

# Synchronous breast cancer and non-Hodgkin lymphoma

*by* Salman Ardi Syamsu

---

**Submission date:** 11-Jul-2022 06:28PM (UTC-0400)

**Submission ID:** 1869377750

**File name:** 1-s2.0-S2210261222006447-main.pdf (5.34M)

**Word count:** 5090

**Character count:** 27408



Case report

## Synchronous breast cancer and non-Hodgkin lymphoma: A case report

Salman Ardi Syamsu<sup>a,b,\*</sup>, Rino Setiady<sup>c</sup>, Nilam Smaradania<sup>a,b</sup>, Prihantono<sup>a</sup>, Febie Irsandy<sup>d</sup>, Muhammad Faruk<sup>c</sup>

<sup>a</sup> Division of Oncology, Department of Surgery, Faculty of Medicine, Hasanuddin University, Makassar, Indonesia

<sup>b</sup> Division of Oncology, Department of Surgery, Dr. Wahidin Sudirohusodo Hospital, Makassar, Indonesia

<sup>c</sup> Department of Surgery, Faculty of Medicine, Hasanuddin University, Makassar, Indonesia

<sup>d</sup> Department of Radiology, Faculty of Medicine, University of Muslim Indonesia, Makassar, Indonesia

### ARTICLE INFO

#### Keywords:

Breast cancer  
Non-Hodgkin lymphoma  
Mastectomy  
Chemotherapy drug  
Synchronous malignancy  
Case report

### ABSTRACT

**Introduction:** Among women, breast cancer (BC) is the most prevalent type of cancer and the top cause of cancer deaths. Although non-Hodgkin lymphoma (NHL) is the most prevalent hematological cancer, it is rarely reported synchronous with BC. Moreover, which malignancy appears first can rarely be explained because they are usually detected incidentally while diagnosing and treating other malignancies. This paper reports a case of invasive ductal carcinoma (IDC) concomitant with NHL.

**Presentation of case:** A 35-year-old woman presented with simultaneous IDC in the left breast and NHL in a lymph node in the neck. The patient underwent a modified radical mastectomy for stage IIIA IDC and received rituximab, cyclophosphamide, doxorubicin, vincristine, and prednisone (R-CHOP) chemotherapy for stage I NHL.

**Clinical discussion:** Treating BC and NHL remains challenging due to their significantly different management, the lack of guidelines for treating BC and lymphoma simultaneously, and uncertainty about whether synchronous tumors should be treated separately as distinct clinical entities or as one disease with treatment covering both. Therefore, the best approach continues to be focusing on the most biologically aggressive malignancies.

**Conclusion:** The enlargement of lymph nodes not in the lymphatic drainage of the primary tumor should be suspected of indicating multiple primary malignancies until proven otherwise. For patients with luminal-B BC, NHL chemotherapy can involve receiving the R-CHOP regimen, including doxorubicin and cyclophosphamide, which can help to mitigate BC.

### 1. Introduction

Among women, breast cancer (BC) is the most prevalent type of cancer and the top cause of cancer deaths [1]. Following chemotherapy or radiotherapy, patients with BC are at greater risk of developing non-Hodgkin lymphoma (NHL), the most prevalent hematological cancer [2]. However, cases of synchronous BC and lymphoma at the time of initial diagnosis have been documented, meaning that lymphoma is not always caused by therapy [3].

BC and NHL rarely appear simultaneously; this coincidence has only been observed in a few cases. We report the first known case in Indonesia, a 35-year-old woman with synchronous invasive ductal carcinoma of the breast and NHL. We are reporting it according to the 2020 Surgical Case Report criteria [4].

### 2. Case presentation

A 35-year-old woman presented with the complaint of a large palpable lump in her left breast and a lump in the left side of her neck, both of which had been present for 2 years. The breast lump was initially as large as 1.0 × 1.5 cm but not painful. The patient reported usually experiencing drenching night sweats and weight loss but did not report any shortness of breath.

The patient had a history of tuberculous lymphadenopathy in the left side of her neck and had undergone treatment for tuberculosis. Her menarche had occurred at 12 years of age, and she was still menstruating at the time of presentation. A year after her marriage, she became pregnant with her first child at 26 years of age, whom she breastfed until the child was 1 year old. She had used contraceptive injections for 1 year

\* Corresponding author at: Division of Oncology, Department of Surgery, Faculty of Medicine, Hasanuddin University, Jalan Perintis Kemerdekaan KM 11, Makassar, South Sulawesi, 90245, Indonesia.

E-mail addresses: [salmanardisyamsu@gmail.com](mailto:salmanardisyamsu@gmail.com) (S.A. Syamsu), [drrinosetiady@gmail.com](mailto:drrinosetiady@gmail.com) (R. Setiady), [nilam.s.adil@gmail.com](mailto:nilam.s.adil@gmail.com) (N. Smaradania), [prihantono@pasca.unhas.ac.id](mailto:prihantono@pasca.unhas.ac.id) (Prihantono), [febie.irsandy.kodratullah@gmail.com](mailto:febie.irsandy.kodratullah@gmail.com) (F. Irsandy), [farox8283@gmail.com](mailto:farox8283@gmail.com) (M. Faruk).

<https://doi.org/10.1016/j.ijscr.2022.107398>

Received 13 May 2022; Received in revised form 21 June 2022; Accepted 6 July 2022

Available online 9 July 2022

2210-2612/© 2022 The Authors. Published by Elsevier Ltd on behalf of IJS Publishing Group Ltd.

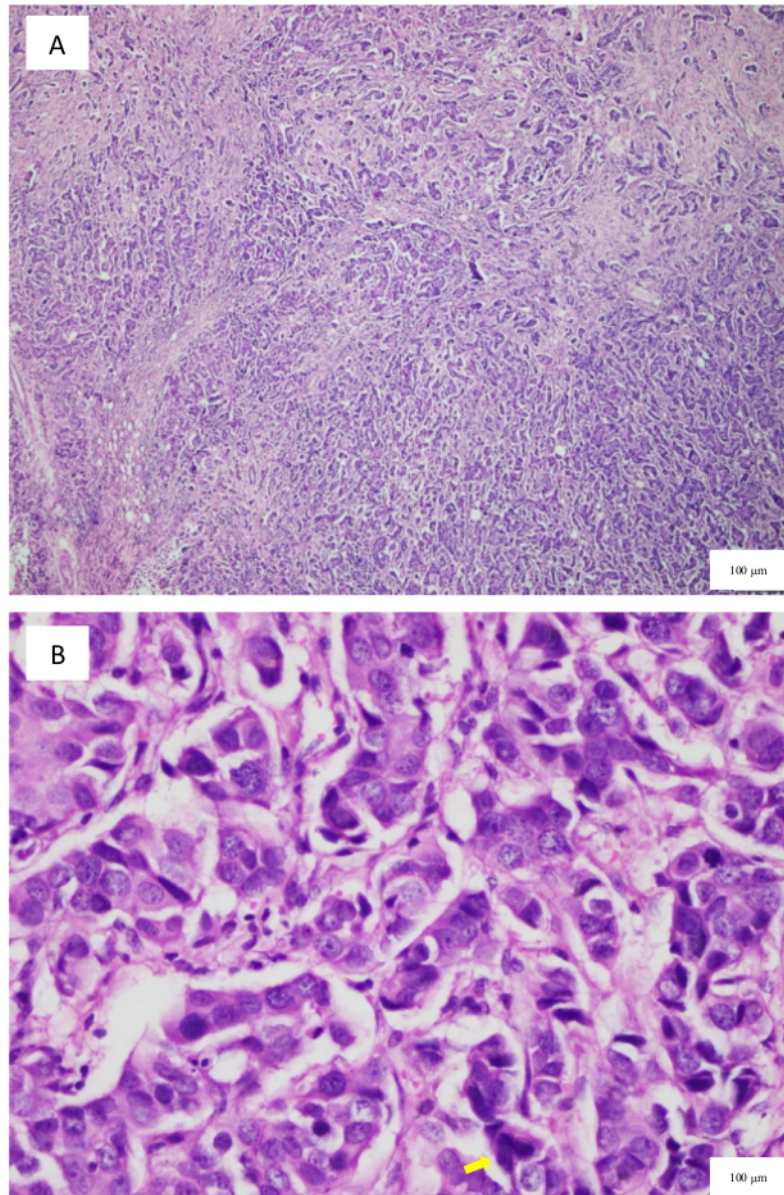
This is an open access article under the CC BY-NC-ND license (<http://creativecommons.org/licenses/by-nc-nd/4.0/>).

but had not sustained any radiation exposure to the thoracic wall.

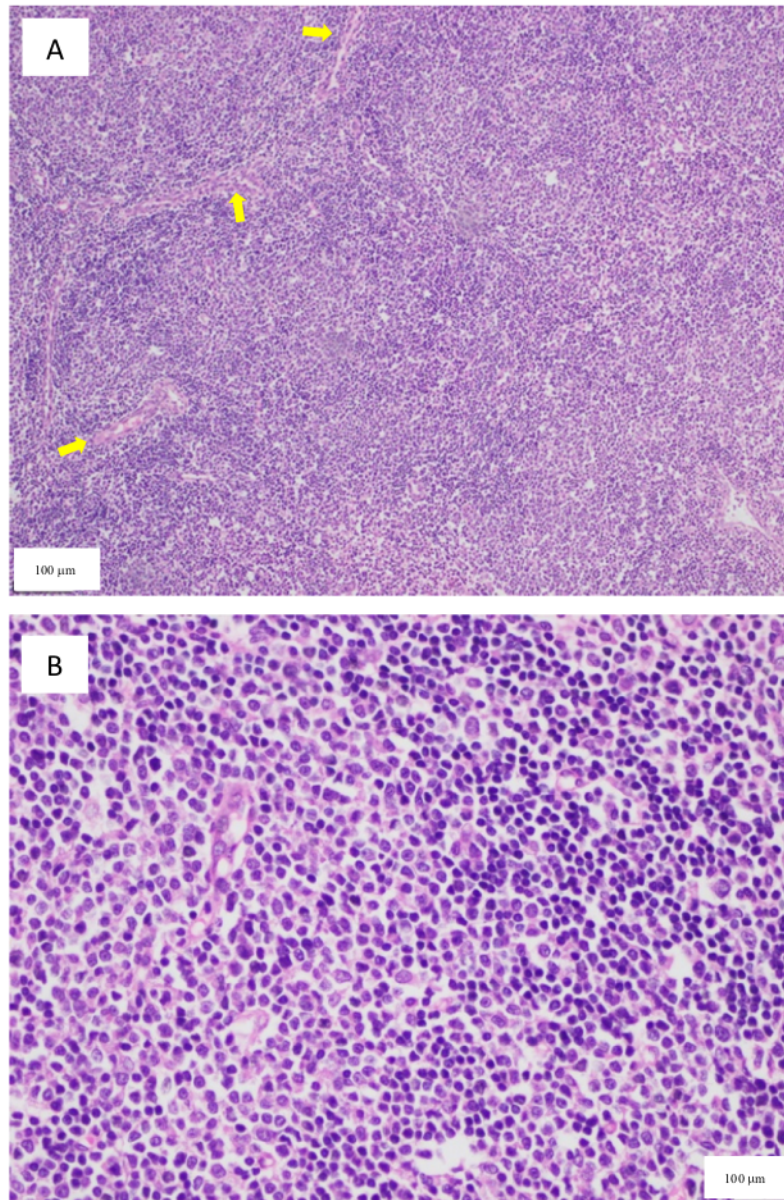
The patient also had a history of fine-needle aspiration (FNA) biopsy in the past two years with adenocarcinoma of the left breast. Eighteen months ago, she had an open biopsy, and the histopathology showed invasive ductal carcinoma with no special type grade III (i.e., poorly differentiated) in the breast and NHL in the neck mass. Meanwhile, immunohistochemistry revealed luminal-B BC (i.e., positive for progesterone receptors [PR], estrogen receptors [ER], and human epidermal growth factor receptor 2 [HER-2]; Fig. 1) and small cell lymphocytic lymphoma (SLL; positive for CD20 and CD45). Immunohistochemistry also revealed that the lymphocytes were positive (Fig. 2). The patient subsequently underwent eight cycles of chemotherapy with

rituximab, cyclophosphamide, doxorubicin, vincristine, and prednisone (R-CHOP) (Fig. 3). After chemotherapy, the lump in the left breast had decreased to 0.5 cm in diameter based on ultrasonography (US) examination (i.e., partial clinical response according to RECIST criteria [1,5]), whereas the lump in the neck had disappeared (i.e., complete clinical response according to RECIL criteria [6]) (Fig. 4). Table 1 shows the timeline of the case.

At admission, the patient's vital signs and body mass index were within normal limits, and her Kamofsky Performance Status score [7,8], a measure used to gauge whether chemotherapy or palliative care is appropriate and whether dose adjustment is necessary, was 90. Clinical examination revealed a firm, painless, mobile, poorly circumscribed



**Fig. 1.** A) Nests of tumors growing infiltratively in the connective tissue stroma, generally in a solid, nested pattern (hematoxylin and eosin, 4 $\times$ ). B) Tumor cells with atypical pleomorphic nuclei, coarse chromatin, prominent nucleoli, and a mitotic appearance (arrow; hematoxylin and eosin, 40 $\times$ ).



**Fig. 2.** A) Distribution of cells with a diffuse effect and blood vessels between them (arrow; hematoxylin and eosin, 10 $\times$ ). B) Distribution of oval cells with minimal small, atypical, relatively monotonous, vesicular nuclei (hematoxylin and eosin, 40 $\times$ ).

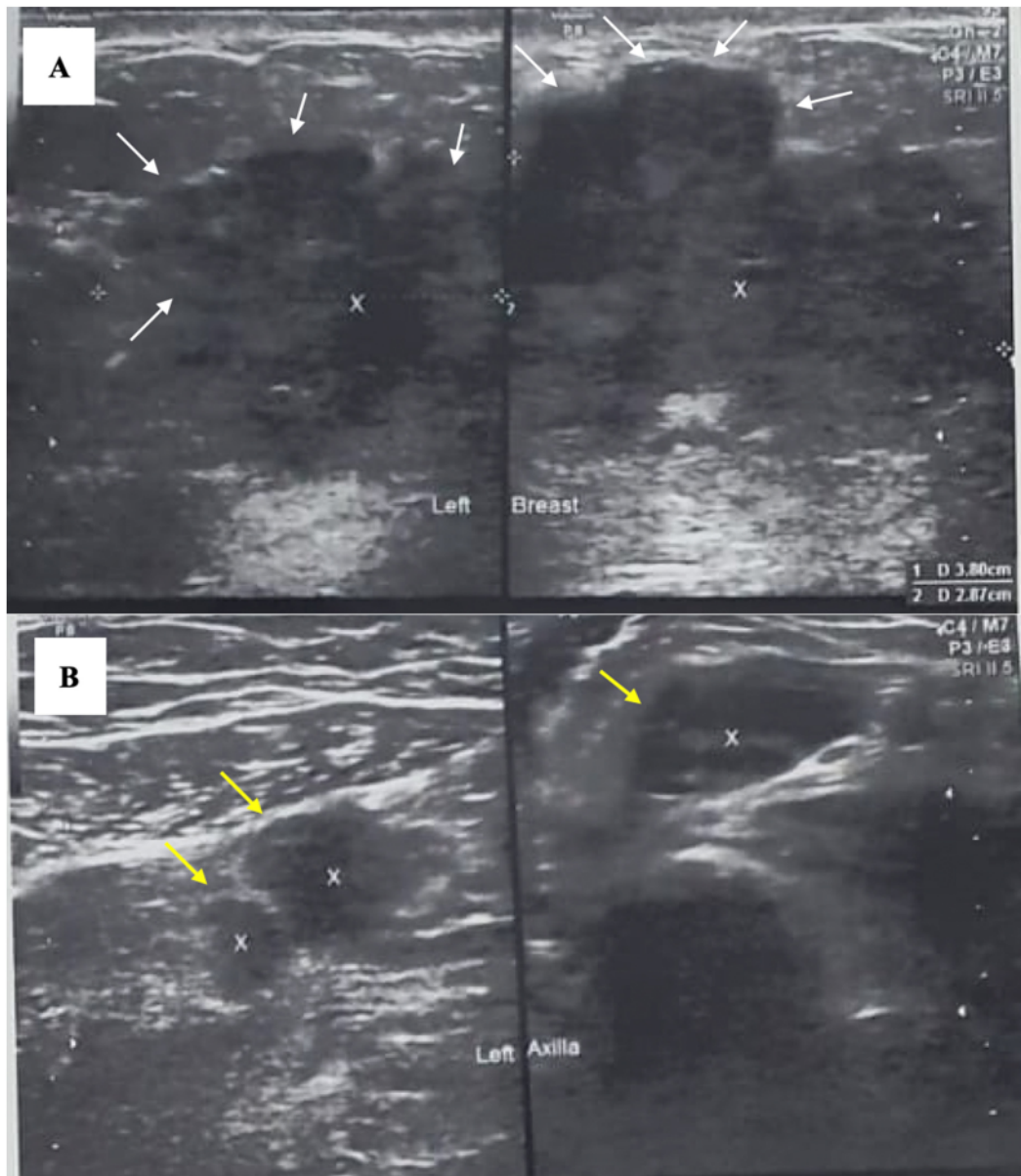
tumor approximately 5  $\times$  4  $\times$  4 cm in the upper outer quadrant of the left breast with no associated lymphadenopathy. Examining the contralateral breast and axilla yielded nothing remarkable, whereas examining the lymph node in the left neck at level III revealed a firm, mobile tumor approximately 1  $\times$  1 cm. US images showed an irregular hypoechoic mass in the left breast and abnormal regional lymph nodes in the left axilla. Laboratory evaluation also yielded nothing remarkable, and a chest X-ray and abdominal ultrasonography showed no signs of metastasis. We, a team of surgical oncologists, thus diagnosed stage IIIA invasive ductal carcinoma in the left breast and stage I SLL according to the Lugano classification.

The patient underwent a left mastectomy followed by adjuvant

chemotherapy with paclitaxel and trastuzumab. She remains in follow up today, 8 months after mastectomy, and has shown satisfying results and no evidence of the tumor's recurrence. We re-evaluated her stage I SLL and are treating it with hormonal therapies, including tamoxifen and goserelin.

### 3. Discussion

In 1889, multiple primary malignancies (MPMs) were first reported by Billroth [9,10]. In 1962, Warren and Gates proposed the following specific criteria for diagnosing MPM: (1) both tumors must have unequivocal histologic evidence of malignancy; (2) histologically, the two



**Fig. 3.** Ultrasonography (US) before chemotherapy: (A) Irregular hypoechoic mass in the left breast and (B) abnormal regional lymph nodes in the left axilla. An irregular hypoechoic mass  $3.8 \times 2.6$  cm in the left breast (white arrows) and multiple enlarged lymph nodes in the left axilla (yellow arrows) were revealed via US. (For interpretation of the references to color in this figure legend, the reader is referred to the web version of this article.)

tumors must be different; and (3) the second tumor cannot be a metastasis of the primary tumor. The occurrence of two or more primary malignant tumors in a single patient was classified as an MPM. MPM is divided into two types, synchronous and metachronous, depending on when the tumors are diagnosed. In synchronous MPM, a second tumor is diagnosed simultaneously or within two months of the first tumor, whereas in metachronous MPM, a second tumor is identified more than six months after the first tumor. In various settings, the prevalence of MPM has ranged from 0.52 to 11.2 % [10,11]. Over seven years, a retrospective clinical study in Shaanxi, China, revealed a 1 % frequency of MPM among 15,683 patients diagnosed with malignant tumors [10].

Women with BC have a greater risk of developing a second malignancy than the overall population. Still, synchronous non-breast cancer is extremely rare in BC patients [10,12]. Synchronous BC and malignant lymphoma are infrequent. Malignant lymphoma is identified in the breast or the ipsilateral axillary lymph nodes in the majority of synchronous BC and malignant lymphoma cases [10]. However, our patient has synchronous BC and malignant lymphoma of the cervical lymph nodes.

MPMs have a complex etiology that has yet to be determined [10,13]. Several potential causal variables of MPMs have been identified, including environmental, intrinsic, therapeutic, and genetic

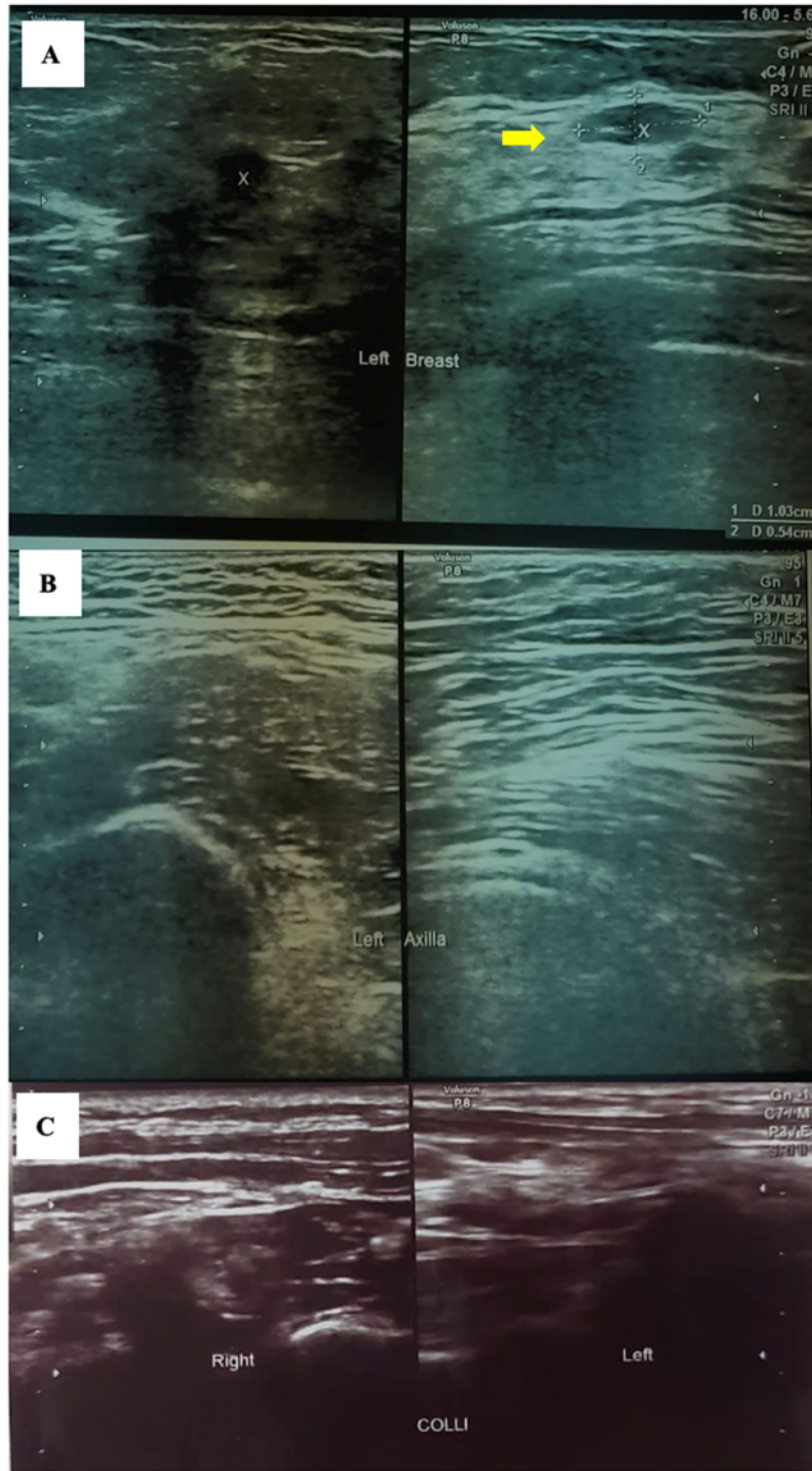


Fig. 4. Ultrasonography after chemotherapy: (A) A regular hypoechoic mass 1.0 × 0.5 cm in the left breast (yellow arrow), (B) no enlarged lymph nodes in the left axilla, and (C) no enlarged lymph nodes in the neck. (For interpretation of the references to color in this figure legend, the reader is referred to the web version of this article.)

**Table 1**  
Timeline of the case.

Dates	Relevant medical history	Diagnostic testing	Interventions
6 January 2019	Summaries from initial and follow-up visits	FNA: Tuberculous lymphadenopathy	Antitubercular drugs for 9 months, after which the patient has remained well and shown no further symptoms
January 2020	<ul style="list-style-type: none"> <li>The breast lump was initially as large as 1.0 × 1.5 cm but painless.</li> <li>The lump in the left side of the neck was initially as large as 1.0 × 0.5 cm.</li> </ul>	FNA: Adenocarcinoma in the left breast and NHL in the neck mass	–
February–October 2020	The Indonesian government imposed a lockdown due to the COVID-19 pandemic so that hospitals temporarily only provided emergency treatment for an emergency case.	Open biopsy:	Eight cycles of chemotherapy with rituximab, cyclophosphamide, doxorubicin, vincristine, and prednisone (R-CHOP)
November 2020	The breast lump was enlarged (3.8 × 2.6 cm), as was the lump in the left side of the neck (1.5 × 1 cm).	<ul style="list-style-type: none"> <li>Invasive ductal carcinoma with no special type grade III (i.e., poorly differentiated) in the left breast</li> <li>NHL, specifically small cell lymphocytic lymphoma, in the neck mass</li> </ul>	
April 2021	<ul style="list-style-type: none"> <li>The lump in the left breast had decreased in size.</li> <li>The lump in the left side of the neck had disappeared.</li> </ul>	Immunohistochemistry: <ul style="list-style-type: none"> <li>Luminal-B breast cancer (i.e., positive for PR, ER, and HER-2)</li> <li>Small cell lymphocytic lymphoma (i.e., positive for CD20 and CD45)</li> </ul>	Surgery scheduled for the following week to remove the tumor. The patient did not return for surgery, however, due to residing in a rural village with little access to public transportation. No follow-up
May–August 2021	–	–	–
September 2021	The patient presented with the complaint of a large palpable lump in her left breast and a lump in the left side of her neck. Clinical examination revealed a firm, painless, mobile, poorly circumscribed tumor approximately 5 × 4 × 4 cm in the upper outer quadrant of the left breast with no associated lymphadenopathy. Examining the contralateral breast and axilla yielded nothing remarkable, whereas examining the lymph node in the left neck at level III revealed a firm, mobile tumor approximately 1 × 1 cm.	US images showed an irregular hypoechoic mass in the left breast and abnormal regional lymph nodes in the left axilla. Laboratory evaluation yielded nothing remarkable, and a chest X-ray and abdominal ultrasonography showed no signs of metastasis.	Left mastectomy
October 2021	The patient remained in follow-up, with no symptoms or evidence of the tumor's recurrence.	<ul style="list-style-type: none"> <li>Physical examination showed no signs of recurrence.</li> <li>Tumor markers Ca-153 and CEA were within normal limits.</li> <li>Chest X-ray and abdominal ultrasonography showed no signs of metastasis.</li> </ul>	Chemotherapy with paclitaxel and trastuzumab
December 2021	The patient remained in follow-up, with no symptoms or evidence of the tumor's recurrence	<ul style="list-style-type: none"> <li>Physical examination showed no signs of recurrence.</li> <li>Tumor markers Ca-153 and CEA were within normal limits.</li> <li>Chest X-ray and abdominal ultrasonography showed no signs of metastasis.</li> </ul>	Chemotherapy with paclitaxel and trastuzumab
June 2022	The patient remains in follow-up, with no symptoms or evidence of the tumor's recurrence	<ul style="list-style-type: none"> <li>Physical examination revealed no signs of recurrence.</li> <li>Tumor markers Ca-153 and CEA were within normal limits.</li> <li>Chest X-ray and abdominal ultrasonography showed no signs of metastasis.</li> </ul>	Tamoxifen and goserelin

Notes: FNA = fine-needle aspiration; NHL = non-Hodgkin lymphoma; COVID-19 = coronavirus disease of 2019; R-CHOP = rituximab, cyclophosphamide, doxorubicin, vincristine, and prednisone; PR = progesterone receptors; ER = estrogen receptors; HER-2 = human epidermal growth factor receptor 2; US = ultrasonography; CD20 = cluster of differentiate 20; CD45 = cluster of differentiate 45; Ca-153 = carcinoma antigen 15-3; CEA = carcinoembryonic antigen.

factors. Long-term exposure to pollution and/or radiation, as well as one's lifestyle, can also play a role, while intrinsic factors may consist of vulnerability, immune status, embryonic development, and endocrine development. Radiation therapy and chemotherapy are the most common therapeutic factors, whereas genetic factors may include genetic alterations [10]. Wiernik et al. [14] have hypothesized that some cases of BC concurrent with lymphoma may share viral origins. Beyond that, Subramanian et al. [15] have hypothesized that the oncogenic

Epstein–Barr virus, which interacts with the Nm23-H1 metastasis suppressor protein to prevent it from inhibiting breast and lymphoma cell migration, is the causative factor of the dissemination of both invasive BC and lymphomas.

Indolent lymphomas, such as the SLL variety, make lymphoma and BC diagnosis difficult. Patients with NHL present with fever, night sweats, and weight loss, also known as B symptoms. Patients with a high-grade variety of NHL are more likely to have systemic B symptoms.

Painless peripheral lymphadenopathy affects more than two thirds of individuals [16]. The majority of patients with early-stage NHL have no obvious symptoms or abnormalities in their lab tests. NHL frequently manifests with adenopathy. In addition to the breast tumor, patients with BC may have axillary adenopathy. Atypical signs and symptoms, as in early-stage BC and distant adenopathy, may lead the treating physician to believe that the patient has synchronous cancer rather than metastatic disease. The diagnosis of synchronous pathology may be overlooked if adenopathy arises only in the axillary lymph nodes or if BC is locally progressed. Therefore, the pathologist should consider performing various IHC stains to differentiate the different diagnoses. When lymphoma is suspected, clinicians should consider running a comprehensive IHC panel, including CD3, CD5, BCL6, CD10, CD20, CD23, and cyclin D1 [17,18]. We conducted an IHC, CD20, and CD 45 examination of this patient, with positive results.

The management of BC and SLL differs significantly, creating yet another challenge. No guidelines presently exist for treating BC and lymphoma simultaneously, and it is unclear whether synchronous tumors should be treated as two different clinical entities with separate treatments or as a single disease with treatment that covers both tumor types. Therefore, the best approach is to focus on the most biologically aggressive malignancies. According to the best practice statement, multidisciplinary teams should discuss and make treatment recommendations based on the initial presentation of each cancer's type and stage, as well as the prognosis of malignancy and current status.

According to the National Comprehensive Cancer Network (NCCN), the first choice of therapy for SLL depends on the disease stage, the presence or absence of TP53 or del(17p) mutations, immunoglobulin heavy-chain variable region gene mutation status, patient age, performance status, presence of comorbid disease, and the toxicity profile of chemotherapeutic agents [18]. The NCCN recommends observation versus locoregional radiotherapy plus anti-CD 20 monoclonal antibody (rituximab, obinutuzumab) therapy. Chemotherapy may be added if the patient has systemic B symptoms or if progressive bulky disease, progressive anemia, and progressive thrombocytopenia are indicated [18,19]. Before therapy, evaluating the fluorescent in situ hybridization for del(17p), TP53 mutation status, and CpG-stimulated karyotype is advisable [18]. However, this examination does not exist in Indonesia. Therefore, we administered R-CHOP chemotherapy. The components of this regimen also contain an AC (doxorubicin/adriamycin and cyclophosphamide) regimen, so it can be helpful for BC as well.

According to NCCN recommendations, tumor, node and metastasis staging is used to determine treatment for invasive BC. The standard of care is still surgery with a modified radical mastectomy or a lumpectomy followed by radiation therapy (breast-conserving therapy [BCT]). BCT is the therapy of choice for early-stage BC, according to recent studies [17]. Chemotherapy regimens for luminal B type are:

- Dense AC dosages, followed by dense paclitaxel doses.
- AC at a high dose, followed by paclitaxel every week.
- Docetaxel in combination with cyclophosphamide.

Surgical oophorectomy and ovarian irradiation are two options for treating ovarian ablation. Luteinizing hormone-releasing hormone (LHRH) agonists can be used to inhibit ovarian estrogen synthesis by inhibiting the secretion of the pituitary follicle-stimulating hormone and luteinizing hormone [20,21]. In Indonesia, the LHRH agonist drugs available include goserelin and leuprolide, to be administered every 1 or 3 months. Adjuvant endocrine therapy with selective estrogen receptor modulators (SERMs) such as tamoxifen or aromatase inhibitors (i.e., toremifene, exemestane, and anastrozole) is recommended for all patients with hormone receptor positive (HR+) BC [17,20]. According to the Early Breast Cancer Trialists' Collaborative Group [22], women with early-stage HR+ BC who received adjuvant SERM or tamoxifen medication for 5 years had a nearly 30 % lower risk of death. In our premenopausal patient with luminal-B BC, we administered AC

chemotherapy with paclitaxel and trastuzumab, followed by endocrine therapy with tamoxifen and ovarian suppression therapy with goserelin.

The prognosis of lymphoma and breast cancer alone is usually poor, and synchronous malignancies will worsen the prognosis. But in our patients, the follow-up to 8 months post-mastectomy indicated satisfying results, with no evidence of the tumor recurrence. Repeated histology and laboratory tests spaced approximately three to six months apart for five years, then annually, are recommended for surveillance. Imaging such as a contrast chest, abdominal, and pelvic computed tomography scan every six months is suggested for up to two years, then every year [17].

#### 4. Conclusion

The enlargement of lymph nodes not in the lymphatic drainage of the primary tumor should be suspected of indicating MPM until proven otherwise. As our rare case of synchronous BC with NHL and brief review of the literature have shown, MPMs can challenge diagnosis and treatment and consequently require the complete staging assessment of both types of tumors in order to determine the best treatment option. For patients with luminal-B BC, NHL chemotherapy can involve receiving the R-CHOP regimen, including doxorubicin and cyclophosphamide, which can help to mitigate BC.

#### Funding

No funding or sponsorship.

#### Ethical approval

The study is exempt from ethical approval in our institution.

#### Consent

Written informed consent was obtained from the patient for publication of this case report and accompanying images. A copy of the written consent is available for review by the Editor-in-Chief of this journal on request.

#### Author contribution

Salman Ardi Syamsu: study concept and surgical therapy for this patient. Salman Ardi Syamsu and Rino Setiady: Data collection and Writing-Original draft preparation. Nilam Smaradania and Prihantono: senior author and the manuscript reviewer. Salman Ardi Syamsu, Rino Setiady and Muhammad Faruk: Editing and Writing. All authors read and approved the final manuscript.

#### Registration of research studies

Not applicable – single case report.

#### Guarantor

Salman Ardi Syamsu

#### Provenance and peer review

Not commissioned, externally peer-reviewed.

#### Declaration of competing interest

Nothing to declare.

## Acknowledgement

A higher appreciation to Bayu Satria M.D for his help in providing us the linguistic assistance for this case report and all staff of the Sentra Diagnostik Patologia Makassar (SDPM), Makassar, Indonesia for the histopathology examination.

## References

- [1] Prihantono, M. Faruk, Breast cancer resistance to chemotherapy: when should we suspect it and how can we prevent it? *Ann. Med. Surg.* 70 (2021), 102793 <https://doi.org/10.1016/j.amsu.2021.102793>.
- [2] K.C. Thandra, A. Barsouk, K. Saginala, S.A. Padala, A. Barsouk, P. Rawla, Epidemiology of non-Hodgkin's lymphoma, *Med. Sci. (Basel, Switzerland)* 9 (2021) 5, <https://doi.org/10.3390/medsci910005>.
- [3] M.H. Hahm, H.J. Kim, K.M. Shin, S.H. Cho, J.Y. Park, J.H. Jung, J.Y. Jeong, J. H. Bae, Concurrent invasive ductal carcinoma of the breast and malignant follicular lymphoma, initially suspected to be metastatic breast cancer: a case report, *J. Breast Cancer* 17 (2014) 91–97, <https://doi.org/10.4048/jbc.2014.17.1.91>.
- [4] R.A. Agha, T. Franchi, C. Sohrali, G. Mathew, A. Kerwan, A. Thoma, A.J. Beamish, A. Noureldin, A. Rao, B. Vasudevan, B. Challacombe, B. Perakath, B. Kirshtein, B. Eksler, C.S. Pramesh, D.M. Laskin, D. Machado-Aranda, D. Miguel, D. Pagano, F. H. Millham, G. Roy, H. Kadioglu, L.J. Nixon, I. Mukhejee, J.A. McCaul, J. Chi-Yong Ngu, J. Albrecht, J.G. Rivas, K. Raveendran, L. Derbyshire, M.H. Ather, M. A. Thorat, M. Valmasoni, M. Bashashati, M. Chalkoo, N.Z. Teo, N. Reason, O. J. Muensterer, P.J. Bradley, P. Goel, P.S. Pai, R.Y. Afifi, R.D. Rosin, R. Coppola, R. Klappenbach, R. Wynn, R.L. De Wilde, S. Surani, S. Giordano, S. Massarut, S. G. Raja, S. Basu, S.A. Enam, T.G. Manning, T. Cross, V.K. Karanth, V. Kasivisvanathan, Z. Mei, The SCARE 2020 guideline: updating consensus Surgical CAse REport (SCARE) guidelines, *Int. J. Surg.* 84 (2020) 226–230, <https://doi.org/10.1016/j.ijsu.2020.10.034>.
- [5] E.A. Eisenhauer, P. Therasse, J. Bogaerts, L.H. Schwartz, D. Sargent, R. Ford, J. Dancy, S. Arbuck, S. Gwyther, M. Mooney, L. Rubinstein, L. Shankar, L. Dodd, R. Kaplan, D. Lacombe, J. Verweij, New response evaluation criteria in solid tumours: revised RECIST guideline (version 1.1), *Eur. J. Cancer* 45 (2009) 228–247, <https://doi.org/10.1016/j.ejca.2008.10.026>.
- [6] A. Younes, P. Hilden, B. Coiffier, A. Hagenbeek, G. Salles, W. Wilson, J.F. Seymour, K. Kelly, J. Gribben, M. Pfreundschuh, F. Morschhauser, H. Schoder, A.D. Zelenetz, J. Rademaker, R. Advani, N. Valente, C. Fortpied, T.E. Witzig, L.H. Sehn, A. Engert, R.I. Fisher, P.-L. Zinzani, M. Federico, M. Hutchings, C. Bollard, M. Trneny, Y. A. Elsayed, K. Tobinai, J.S. Abramson, N. Fowler, A. Goy, M. Smith, S. Ansell, J. Kuruvilla, M. Dreyling, C. Thieblemont, R.F. Little, I. Auer, M.H.J. Van Oers, K. Takeshita, A. Gopal, S. Rule, S. de Vos, I. Kloos, M.S. Kaminski, M. Meignan, L. H. Schwartz, J.P. Leonard, S.J. Schuster, V.E. Seshan, International Working Group consensus response evaluation criteria in lymphoma (RECIL 2017), *Ann. Oncol.* 28 (2017) 1436–1447, <https://doi.org/10.1093/annonc/mdx097>.
- [7] H.(Jack) West, J.O. Jin, Performance status in patients with cancer, *JAMA Oncol.* 1 (2015) 998, <https://doi.org/10.1001/jamaoncol.2015.3113>.
- [8] D. Péus, N. Newcomb, S. Hofer, Appraisal of the Karnofsky Performance Status and proposal of a simple algorithmic system for its evaluation, *BMC Med. Inform. Decis. Mak.* 13 (2013) 72, <https://doi.org/10.1186/1472-6947-13-72>.
- [9] C. Zhai, Y. Cai, F. Lou, Z. Liu, J. Xie, X. Zhou, Z. Wang, Y. Fang, H. Pan, W. Han, Multiple primary malignant tumors - a clinical analysis of 15,321 patients with malignancies at a single center in China, *J. Cancer* 9 (2018) 2795–2801, <https://doi.org/10.7150/jca.25482>.
- [10] N.S. Salemis, Synchronous occurrence of breast cancer and refractory diffuse large B-cell abdominal lymphoma: management and review of the literature, *Intractable Rare Dis. Res.* 10 (2021) 131–135, <https://doi.org/10.5582/irdr.2021.01017>.
- [11] A. Irimie, P. Achimas-Cadariu, C. Burz, E. Puscas, Multiple primary malignancies—epidemiological analysis at a single tertiary institution, *J. Gastrointest. Liver Dis.* 19 (2010) 69–73, <http://www.ncbi.nlm.nih.gov/pubmed/20361078>, <http://www.ncbi.nlm.nih.gov/pubmed/20361078>.
- [12] Y.M. Kirova, Y.De Ryckel, G. Gambotti, J.-Y. Pierga, B. Asselain, A. Fourquet, Institut Curie Breast Cancer Study Group, Second malignancies after breast cancer: the impact of different treatment modalities, *Br. J. Cancer* 98 (2008) 870–874, <https://doi.org/10.1038/sj.bjc.6604241>.
- [13] C. Ho, S. Mantoo, C. Lim, C. Wong, Synchronous invasive ductal carcinoma and intravascular large B-cell lymphoma of the breast: a case report and review of the literature, *World J. Surg. Oncol.* 12 (2014) 88, <https://doi.org/10.1186/1477-7819-12-88>.
- [14] P.H. Wiernik, X. Hu, H. Ratech, S. Fineberg, P. Marino, M.A. Schleider, P. Etkind, J.A. Walewski, Non-Hodgkin's lymphoma in women with breast cancer., *Cancer J.* 6 (n.d.) 336–42, <http://www.ncbi.nlm.nih.gov/pubmed/11079174>.
- [15] C. Subramanian, M.A. Cotter, E.S. Robertson, Epstein-Barr virus nuclear protein EBNA-3C interacts with the human metastatic suppressor Nm23-H1: a molecular link to cancer metastasis, *Nat. Med.* 7 (2001) 350–355, <https://doi.org/10.1038/85499>.
- [16] S. Sapkota, H. Shaikh, Non-Hodgkin lymphoma, *StatPearls*, 2022, <http://www.ncbi.nlm.nih.gov/pubmed/32644754>. (Accessed 1 April 2022).
- [17] T. Saleem, K. Mi, R. Pathak, K. Yari, K. Lu, Concurrent breast carcinoma and follicular lymphoma: a case series, *Am. J. Case Rep.* 22 (2021), e931772, <https://doi.org/10.12659/AJCR.931772>.
- [18] W.G. Wierda, J. Brown, J.S. Abramson, F. Awan, S.F. Bilgrami, G. Bociek, D. Brander, A.A. Chanan-Khan, S.E. Coutre, R.S. Davis, H. Eradat, C.D. Fletcher, S. Gaballa, A. Ghobadi, M.S. Hamid, F. Hernandez-Ilizaliturri, B. Hill, P. Kaesberg, M. Kamdar, L.D. Kaplan, N. Khan, T.J. Kipps, S. Ma, A. Mato, C. Mosse, S. Schuster, T. Siddiqi, D.M. Stephens, C. Ujjani, N. Wagner-Johnston, J.A. Woyach, J.C. Ye, Chronic lymphocytic leukemia/small lymphocytic lymphoma, in: *Plymouth Meeting, 2nd ed.*, National Comprehensive Cancer Network, Inc, 2022 <https://www.nccn.org/guidelines/guidelines-detail?category=1&id=1478>.
- [19] B.D. Cheson, R.I. Fisher, S.F. Barrington, F. Cavalli, L.H. Schwartz, E. Zucca, T. A. Lister, Recommendations for initial evaluation, staging, and response assessment of Hodgkin and non-Hodgkin lymphoma: the Lugano classification, *J. Clin. Oncol.* 32 (2014) 3059–3067, <https://doi.org/10.1200/JCO.2013.54.8800>.
- [20] W.J. Gradishar, B.O.B. Anderson, J. Abraham, R. Aft, D. Agnese, K.H. Allison, S. L. Blair, H.J. Burstein, C. Dang, A.D. Elias, S.H. Giordano, M.P. Goetz, L. J. Goldstein, S.J. Isakoff, J. Krishnamurthy, J. Lyons, P.K. Marcom, J. Matro, I. A. Mayer, M.S. Moran, J. Mortimer, R.M. O'Regan, S.A. Patel, L.J. Pierce, H. S. Rugo, A. Sitapati, K.L. Smith, M. Lou Smith, H. Soliman, E.M. Stringer-Reasor, M. L. Telli, J.H. Ward, J.S. Young, J.L. Burns, R. Kumar, J. Abraham, R. Aft, D. Agnese, K.H. Allison, B.O.B. Anderson, H.J. Burstein, H. Chew, C. Dang, A.D. Elias, S. H. Giordano, M.P. Goetz, L.J. Goldstein, S.A. Hurvitz, S.J. Isakoff, R.C. Jankowitz, S.H. Javid, J. Krishnamurthy, M. Leitch, J. Lyons, J. Mortimer, S.A. Patel, L. J. Pierce, L.H. Rosenberger, H.S. Rugo, A. Sitapati, K.L. Smith, M. Lou Smith, H. Soliman, E.M. Stringer-Reasor, M.L. Telli, J.H. Ward, K.B. Wisinski, J.S. Young, Breast cancer, in: *Plymouth Meeting, 3rd ed.*, National Comprehensive Cancer Network Inc, 2022 <https://doi.org/10.6004/jnccn.2020.0016>.
- [21] D.R. Andriyanto, S.A. Prihantono, M.I. Syamsu, J.Hendarto Kusuma, N. Indra, E. Smardania, A. Sampepajung, M.Faruk Mappiwali, Comparison of outcomes in patients with luminal type breast cancer treated with a gonadotropin-releasing hormone analog or bilateral salpingo-oophorectomy: a cohort retrospective study, *Ann. Med. Surg.* 77 (2022), 103614, <https://doi.org/10.1016/j.amsu.2022.103614>.
- [22] R. Bradley, J. Braybrooke, R. Gray, R.K. Hills, Z. Liu, H. Pan, R. Peto, D. Dodwell, P. McGale, C. Taylor, P.A. Francis, M. Gnani, F. Perrone, M.M. Regan, R. Berry, C. Boddington, M. Clarke, C. Davies, L. Davies, F. Duane, V. Evans, J. Gay, L. Gettins, J. Godwin, S. James, H. Liu, E. MacKinnon, G. Mannu, T. McHugh, P. Morris, S. Read, E. Stratton, R. Jakesz, C. Fesl, O. Pagani, R. Gelber, M. De Laurentiis, S. De Placido, C. Gallo, K. Albain, S. Anderson, R. Arriagada, J. Bartlett, E. Bergsten-Nordström, J. Bliss, E. Brain, L. Carey, R. Coleman, J. Cuzick, N. Davidson, L. Del Mastro, A. Di Leo, J. Dignam, M. Dowsett, B. Ejertsen, M. Goetz, P. Goodwin, P. Halpin-Murphy, D. Hayes, C. Hill, R. Jaggi, W. Janni, S. Loibl, E.P. Mamounas, M. Martín, H. Mukai, V. Nekljudova, L. Norton, Y. Ohashi, L. Pierce, P. Poortmans, K.I. Pritchard, V. Raina, D. Rea, J. Robertson, E. Rutgers, T. Spanic, J. Sparano, G. Steger, G. Tang, M. Toi, A. Tutt, G. Viale, X. Wang, T. Whelan, N. Wilcken, N. Wolmark, D. Cameron, J. Bergh, S.M. Swain, Aromatase inhibitors versus tamoxifen in premenopausal women with oestrogen receptor-positive early-stage breast cancer treated with ovarian suppression: a patient-level meta-analysis of 7030 women from four randomised trials, *Lancet Oncol.* 23 (2022) 382–392, [https://doi.org/10.1016/S1470-2045\(21\)00758-0](https://doi.org/10.1016/S1470-2045(21)00758-0).

# Synchronous breast cancer and non-Hodgkin lymphoma

## ORIGINALITY REPORT

4%

SIMILARITY INDEX

2%

INTERNET SOURCES

4%

PUBLICATIONS

0%

STUDENT PAPERS

## PRIMARY SOURCES

- 1** B. N. J. Thomson, R. W. Parks, K. K. Madhavan, S. J. Wigmore, O. J. Garden. "Early specialist repair of biliary injury", *British Journal of Surgery*, 2006  
Publication 1%
- 2** econstor.eu  
Internet Source 1%
- 3** M A Akib, K Mustari, T Kuswinanti, S A Syaiful. "Abundance of arbuscular mychorrizal fungi in rehabilitation area of nickel post-mining land of Sorowako, South Sulawesi", *IOP Conference Series: Earth and Environmental Science*, 2018  
Publication <1%
- 4** Megan E. Tesch, Ann H. Partridge. "Treatment of Breast Cancer in Young Adults", *American Society of Clinical Oncology Educational Book*, 2022  
Publication <1%
- 5** Mohammad Fahad Ullah. "Chapter 4 Breast Cancer: Current Perspectives on the Disease" <1%

# Status", Springer Science and Business Media LLC, 2019

Publication

---

6	<a href="http://almachallenge.blogspot.com">almachallenge.blogspot.com</a> Internet Source	<1 %
7	<a href="http://api.crossref.org">api.crossref.org</a> Internet Source	<1 %
8	<a href="http://ebin.pub">ebin.pub</a> Internet Source	<1 %

---

Exclude quotes On

Exclude matches Off

Exclude bibliography On